

炎症を伴ったPMLの分類

研究分担者: 東京医科歯科大学大学院脳神経病態学分野 三條伸夫

診療ガイドラインの策定・改訂

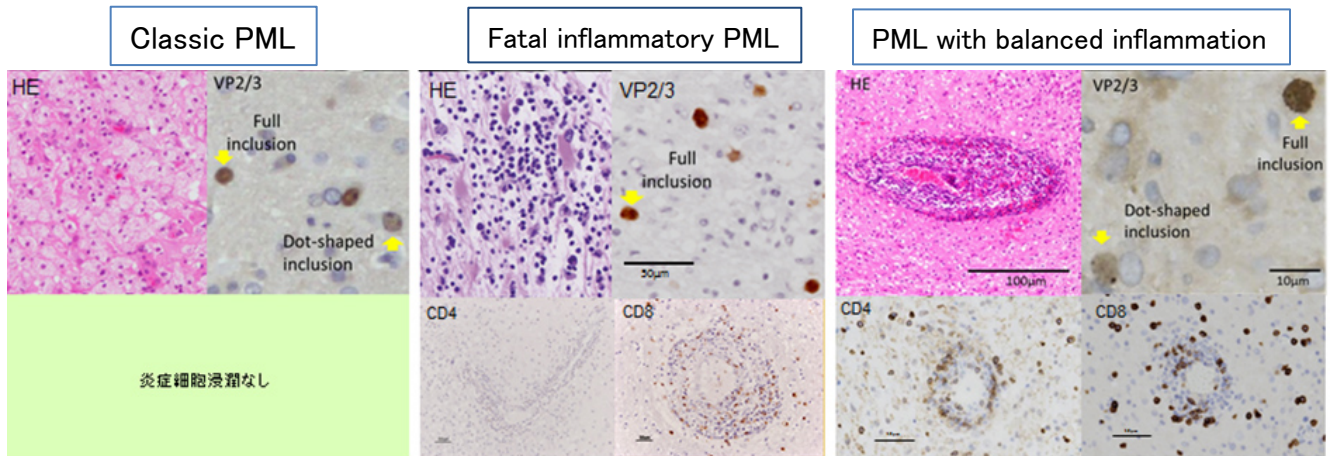
Table. Classification of PML by Inflammation Pattern.

	classic PML	Fatal Inflammatory PML*	PML with balanced inflammation
MRI			
Brain oedema	-	+ to ++	± to +
Peripheral Gd enhancement at the lesion	-	Speckles and/or linear	Speckles and/or linear
Brain pathology			
T cell profile	No infiltration	CD8 predominant	CD4 > = CD8
Inclusions in infected oligodendrocyte	Dotlike to full inclusion	Dotlike to full inclusion	Dotlike predominant
Treatment			
Steroid	Not recommend	Recommend	Not recommend
Mefloquine	Recommend	Recommend	Recommend

PML: Progressive multifocal leukoencephalopathy, MRI: magnetic resonance imaging, Gd: gadolinium

* Including Fatal PML-IRIS in the context of this manuscript.

IRIS: immune reconstitution inflammatory syndrome



解説

1. 脳生検結果より炎症性PMLと診断し、いわゆるfatal immune reconstitution inflammatory syndrome (IRIS)とは異なる病態であることを病理学的に示した。
2. Fatal inflammatory PMLとPML with balanced inflammationは治療方針、予後が異なっており、正確な診断が重要である。